

Study of Vessel Conditions in Different Categories of Weight for Early-Stage of Deep Vein Thrombosis (DVT) Diagnosis

Noor Hafizzatul 'Izzah bt Mat Harun¹, Nabilah bt Ibrahim¹, Wan Nurshazwani bt Wan Zakaria¹, Nik Farhan bin Nik Fuad², Nur Shazilah bt Aziz¹

¹Faculty of Electrical and Electronic Engineering, Universiti Tun Hussein Onn Malaysia, 86400 Batu Pahat, Johor, Malaysia.

²Department of Radiology, Pusat Perubatan Universiti Kebangsaan Malaysia, Bandar Tun Razak, 56000 Cheras, Kuala Lumpur.

Abstract—In this paper, the clinical experiment study is presented to diagnose the Deep Vein Thrombosis (DVT). The diagnosis of DVT is commonly used by monitoring the blood velocity and the present of thrombus in vessel from B-mode ultrasound image associated with the application of Doppler ultrasound. However, the monitoring of those parameters will only be confirmed when someone had already suffered from DVT disease. Thus, this study is to diagnose the early stage of DVT. Since it is difficult to recognize the vessel condition at the early stage of DVT, the evaluation of vein mechanism based on different categories of weight at the early stage of DVT is proposed. The wall displacement and blood flow velocity is considered to be the important parameters to construct a clinical model of DVT risk factor, thereby constitutes an important contribution for predicting probability of Deep Vein Thrombosis (DVT).

Keywords—Ultrasound scan, early diagnosis, wall displacement, blood flow velocity, Deep Vein Thrombosis (DVT)

1. Introduction

Deep vein thrombosis (DVT) is a condition where there is a blood clot develops deep in the vein in the body. The veins that are close to the skin are the superficial veins. The clots mostly found or develop in the lower leg or thighs. However, it may also appear in the upper body such as the arms or other locations [1]. Moreover, patient that has higher probability to have DVT are the patient who had history of surgery on the legs or hips [1]. It can give a serious threat to the health of the patient.

The mechanism of one-way valves, which is inside the vein, is to prevent the back-flow of blood between the contractions. Blood is squeezed up the leg against gravity and the valves prevent it from flowing back to our feet. An ideal setting for clot formation can occur when the circulation of the blood slows down due to illness, injury or inactivity, blood can accumulate or "pool" [2]. A condition of pulmonary embolism is stimulated as the pieces of clots can break up and travel through the bloodstream to the lungs. This condition will lead to fatal soon after it occurs.

There are some factors that contribute to the formation or development of clots in the veins. One of the factors is stasis or stagnant blood through the veins [3]. It increases the contact between the blood and the vein wall irregularities. It also prevents naturally occurring anticoagulant from mixing with the blood. Moreover, prolonged the bed rest or immobility will leads to stasis.

Besides, coagulation also contributes to the clot formation [3].

Additionally, the vein wall can also be damaged during the surgery if the physician retracts soft tissues as part of the procedure [3]. To recognize the DVT, there are some physical symptoms that show the person might possess DVT condition. The symptoms are swelling of the leg, a cord in a leg vein that can be felt, rapid heartbeat, slight fever, dull ache tightness, tenderness in the leg and also more visible surface veins. However, by using only clinical signs, it cannot be confirmed that the patients are having DVT. Therefore, various diagnostic techniques have been used to identify DVT. The methods used include impedance plethysmography, contrast venography, ultrasonography, computed tomography, and magnetic resonance imaging. Before, contrast venography was considered to be the gold standard method in determining the DVT.

However, due to its excessive expenditure in manpower resources and time, the need for specialized personnel, space and equipment, and its limited availability and associated morbidity [4], contrast venography has been replaced with other tests which is more favorable risk or benefit profiles. Moreover, there is D-dimer test that also being used in diagnosing the DVT. A D-dimer test is a blood test that measures a substance released as a blood clot breaks up. D-dimer levels higher than normal that apply to the people who possess a blood clot in the blood vessel [5]. Among these

*Corresponding author: hafizzatul215@gmail.com

method applied, ultrasonography is as accurate as any, with more advantages than CT, MRI, plethysmography and D-dimer test, including low cost, portability, non-invasiveness, and simplicity.

Thus, ultrasound technology is employed which shows a numbers of successful DVT diagnosis [6]. Since deep vein thrombosis (DVT) can give serious threat to the health condition, it is essential to diagnose the DVT condition at the early stage. The diagnosis at this level could help in treating or improving the condition of patients with the DVT. The most common diagnoses done by the physicians are using the clinical assessment. However, the result shown that the condition of the patient still cannot be confirmed [7]. Even by using the D-dimer test, there were still low probabilities in confirmation of the patient having the DVT [8].

Therefore, as a solution for this problem, diagnose by using the ultrasound imaging is proposed which requires no contrast medium and can be performed at the bedside condition. The important parameters that will be evaluates are the wall displacement and the blood flow velocity of the popliteal vein. The vein mechanisms can be analyzed based on those measurements obtained.

2. Method

2.1 Experimental Procedure

To study the vessel condition from different category of the weight, the volunteered subjects had been categorized into three categories of weight that are normal weight, underweight and overweight. The body mass index (BMI) of the subjects will be calculated and categorized into respective categories. There are twelve subjects that had been examined voluntarily. The equipment used for the experiment is the TOSHIBA SSA-580A ultrasound machine. In the scanning of the leg, the linear transducer with frequency range of 6MHz to 12MHz is used.

The patient can be placed in either a prone position, or seated on the edge of the bed with the knee flexed and the foot supported. In the prone positions the leg being examined should be down as shown in Fig. 1.

The procedure to scan the vein is as follows:

- a) Measure BMI of each subject.
- b) Taking blood pressure measurement of subject using electronics blood pressure monitor in rest condition.
- c) Positioned the subject to do the scanning at the popliteal crease.
- d) Apply gel at the scanning area.
- e) Do the scanning of popliteal vein.

- f) After determining the popliteal vein, apply compression to the area to observe if there is any thrombus.
- g) Find the location of the valve.
- h) Measured the velocity before and after the valve.

Video of the scanning is recorded directly from the ultrasound machine in range of 30 seconds to 60 seconds, using external frame grabber DVI2USB 3.0. This video is recorded for the vein wall displacement measurement. The sonographic evaluation is performed by compressing the vein directly using the transducer simultaneously watching for complete apposition of the anterior and posterior walls.

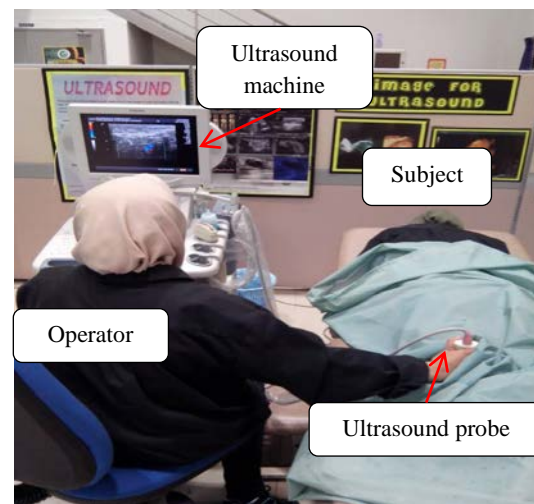

Fig. 1 Leg scanning of the subject using ultrasound.

If complete venous compression is not attained with pressures sufficient to deform the vein, obstructing venous thrombus is likely to be present. Then, scanning of the valve located in the vein as to study the velocity measurement before and after the valve.

During the scanning of the popliteal vein, the location of the vein needed to be determined instead of the artery. As shown in Fig. 2. (a), the pulse wave is seen within popliteal artery gate. While in Fig. 2. (b), the popliteal vein produces complete absence of flow. This result shows that no pulse is detected at the vein. The reason is that the arteries are the blood vessels taking blood away from the heart. The heart is a very powerful muscle; therefore, the blood is ejected out at high pressure and the pulses coincide with the squeezing of the heart [9]. While in veins, the blood is carried back to the heart from tissues.

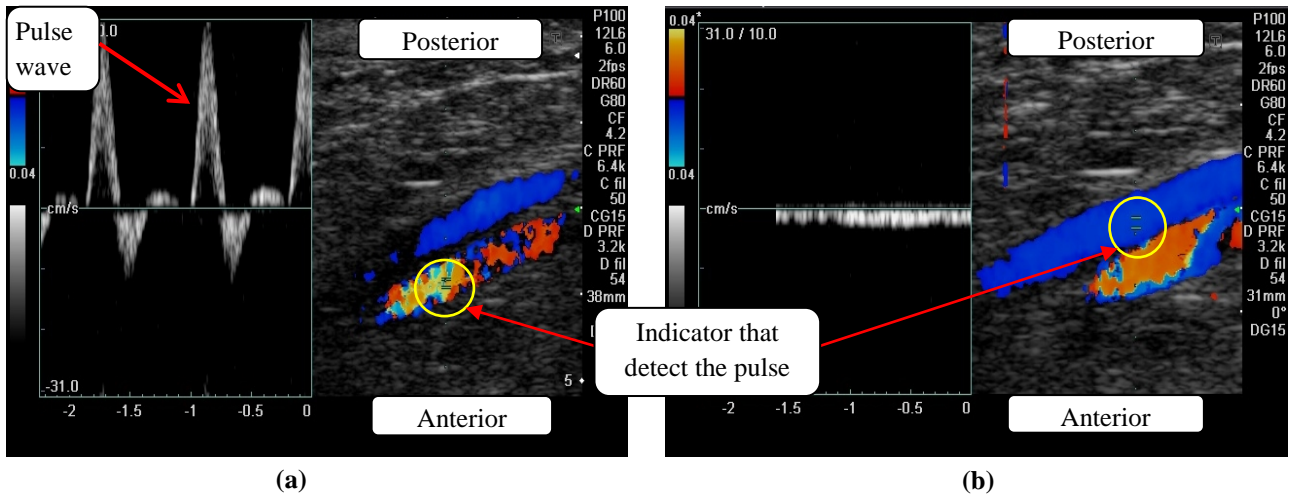


Fig. 2 Doppler color image from ultrasound; (a) indicate the popliteal artery, (b) indicate the popliteal vein.

The blood is not being pushed back from the heart; therefore it has low pressure and no pulse present [9]. Using this approach, the operator could differentiate between the popliteal vein and artery.

2.2 Region of Interest (ROI)

In the study, the region of interest that being scans focusing on the area of valve in the popliteal vein. The ROI chosen due to the necessity of doing the measurement for the displacement between the popliteal vein wall. The valve patency shows that the opening and closing during the blood flow. Therefore, by having the valve scanning area; it will allow to measure the significant changes of the displacement in between the wall of the popliteal vein. The measurement obtained for the vein wall displacement is at the location near the valve area.

2.2 Image Processing

In the evaluation of the video obtain from the leg scanning; Canny edge detection method had been used for the process. Canny edge detection algorithm is known to many as the optimal edge detector [10]. Canny operator is the result of solving an optimization problem with constraints. The criteria are sensibility, localization and local unity. The method can be seen as a smoothing filtering performed with a linear combination of exponential functions, followed by derivative operations [10]. Fig. 3 shows the scanning of the valve that had been located in the vein using the ultrasound machine. Fig. 4 shows the image from the video that had been extracted and the Canny edge detection method applied on it. The image processed using the MATLAB Simulink software.

The edge detection block for Canny, purposely used to find the edges by looking for local maxima of the gradient of the input image. It calculates the gradient using derivative of the Gaussian filter. In Canny method, it uses two thresholds which is the magnitude that detects the strong and weak edges. In Simulink, the threshold value for detecting strong and weak edges was automatically

decided and can be applied to the image being process appropriately. After determining the edges of the vessel wall, the measurement of the wall displacement is collected.

The marked points in the image were to determine the displacement of the vessel wall. The marked point specifically marked at the area near the valve to observe the displacement changes of the vessel wall. This is due to the thrombus developments that usually form in regions of slow or disturbed flow in large venous while for the deep vein of the calf; the thrombus usually forms in the valve cusps pocket [11].

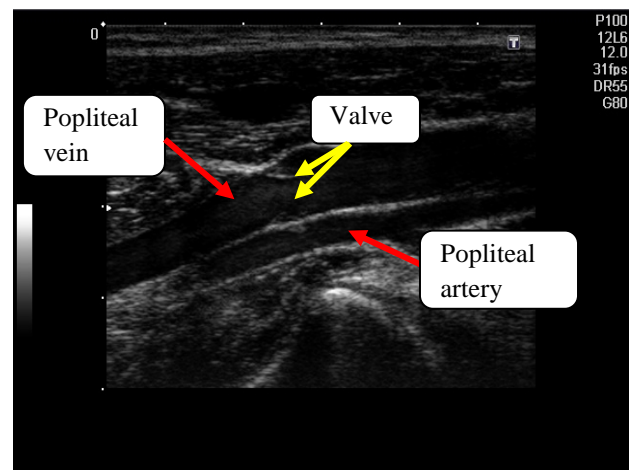


Fig. 3 B-mode image of valve in the region of popliteal vein, the popliteal vein positioned side by side to the popliteal artery.

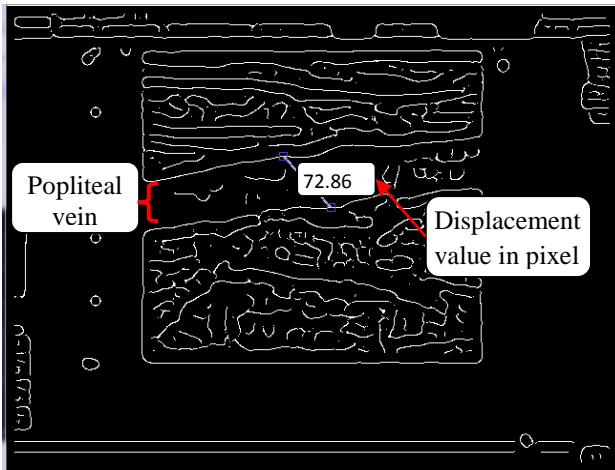


Fig. 4 Extracted image of popliteal vein from recorded video, image processing using Canny edge detection method.

3. Result

In this study, the elasticity of the vein obtained from the calculation. In order to obtain the elasticity, stress and strain measurements are required. Below shows an equation analogous to Hooke’s law describes the relationship between stress and strain [12]:

$$E \text{ (kPa)} = \frac{\text{Stress}}{\text{Strain}} = \frac{\sigma}{\epsilon} = \frac{\frac{F}{A_0}}{\frac{L-L_0}{L_0}} = \frac{FL_0}{A_0\Delta L}, \quad (1)$$

where

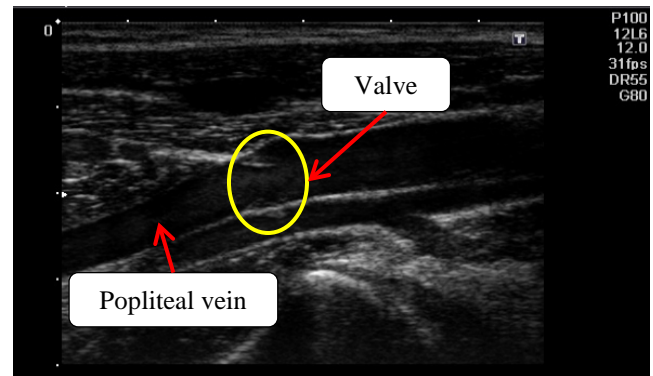
- E : Young's modulus (modulus of elasticity)
- F : Force exerted on an object under tension
- A₀: Original cross-sectional area through which the force is applied
- ΔL: Amount by which the length of the object changes
- L₀: Original length of the object

Stress is the force per unit cross-sectional area (F/A). In example, pull on an elastic band - stretching it from an initial length L₀ to a final length L. The stress is the force we apply, divided by the area of the band in cross section. Strain is the fractional increase in length, that is, (L - L₀)/L₀. The wall displacement measurement is to indicate the strain value for the elasticity of the vein. The stress values obtain from the blood pressure measurement in the vein over the area of the vein.

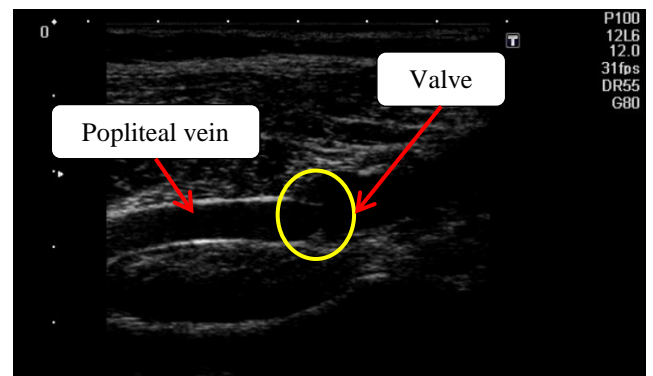
The measurement obtained for each one seconds in range of 10 seconds continuously. While for the stress, value obtains from the blood pressure measurement in the vein over the area of the vein. The blood pressure of vein in the physiologic condition used is 10 mmHg [13].

3.1 Wall displacement

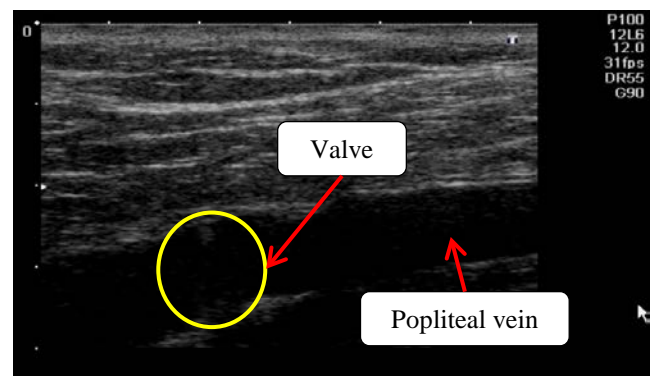
Wall displacement measurements obtain from the image processed in the MATLAB software extracted from the video. The displacement between the walls; taken for 10 seconds continuously. Therefore, strain measurement had been calculated for the vein wall elasticity. Fig. 6 shows the measurement of vessel wall elasticity obtained. The elasticity measurement results for the three categories of weight that are underweight (UW), normal weight (NW), and overweight (OW). In Fig. 5, it shows the sample of image for each category of weight.



(a)



(b)



(c)

Fig. 5 B-mode ultrasound image of popliteal vein for three categories of weight; (a) underweight, (b) normal weight, and (c) overweight.

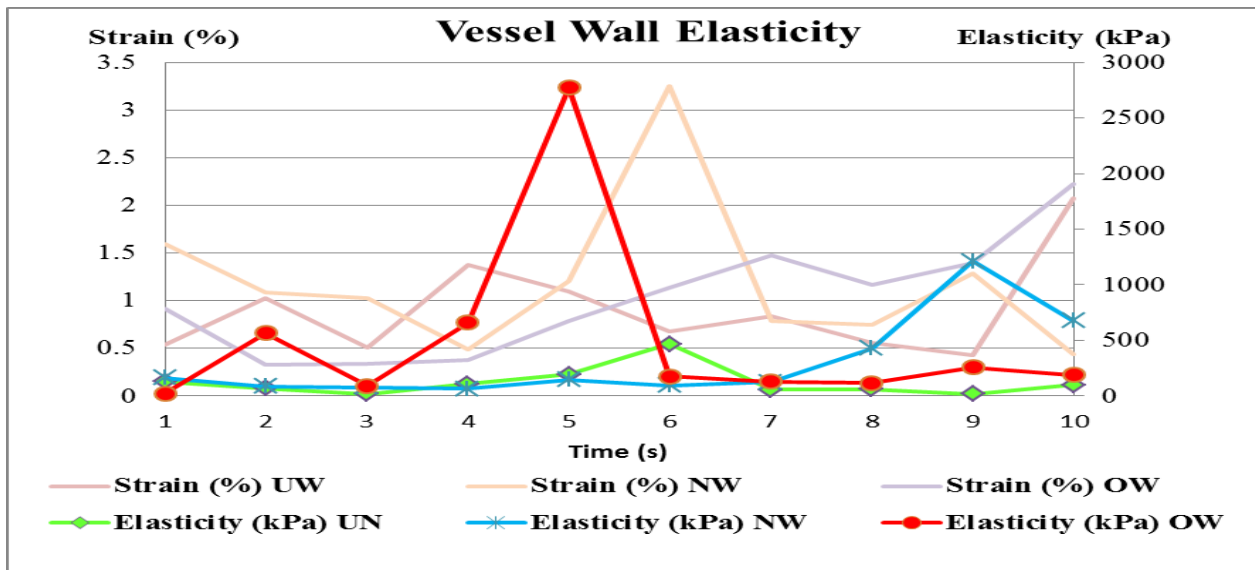


Fig. 6 Vessel wall elasticity measurement for the vein.

Based on the result obtained, the strain-elasticity measurement shows that there is significant different in the elasticity measurement between the underweight, normal weight and overweight category. It can be observed that the overweight category has the highest range of elasticity in comparison to the underweight and the normal weight category.

While for the underweight category shows that it has the lowest range of elasticity for the vessel wall in comparison to the normal group and the overweight group of subjects. As for the normal weight category, it falls into the median range of the elasticity between the underweight and normal weight category.

From recorded study, in contrast to the arterial system, the lower pressure in the venous system not undergoes large changes in capacity without major pressure changes [14]. In the study, Attinger also stated that the cross section of the venous segment may oscillate between complete collapse and full distension depending upon the interplay between intravascular and extravascular forces in relation to the stiffness exhibited by the vascular wall at any given time.

3.2 Blood flow velocity

Blood flow velocity is measurement taken using the Doppler ultrasound. The measurement was taken before and after the valve in the popliteal vein. The average velocity of the blood flow was calculated as to obtain the velocity in the vein. Fig. 7 shows the measurement or the velocity of blood flow in the popliteal vein. This is to study the condition of the vessel based on the velocity obtained.

The measurements of both values are also related to the condition of the subjects. Some factors that might be affecting the measurement are the muscle bulk at the leg of subjects and also the tissue layer content at the region of scanning.

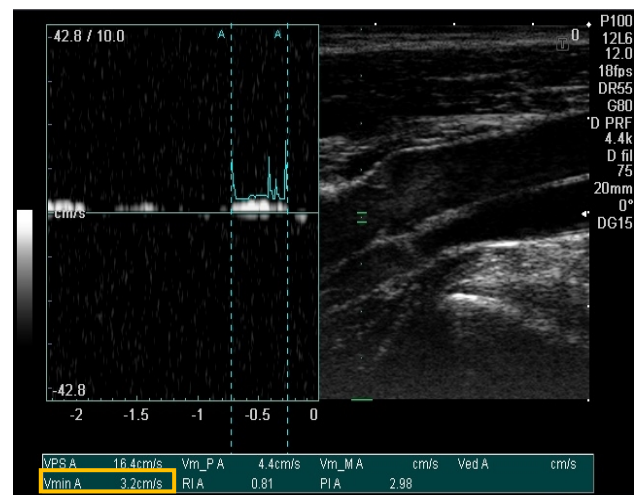


Fig. 7 Velocity measurement of the subject using pulse Doppler ultrasound.

Table 1. Average velocity of blood flow in vein using pulse Doppler ultrasound.

Subject	Average Velocity (cm/s)	
	Before valve	After valve
Under weight	4.2	2.7
Over weight	3.35	4.05
Normal weight	3.38	2.82

From Table 1, it shows the significant differences in the elasticity of the vessel wall and also the blood flow velocity measured. It shows irregular pattern of the blood

flow velocity measurement. The value of the velocity reported can be in range of 20cm/s or lower [15]. The average range of blood flow velocity is 3.575 ± 2.146 cm/s (before the valve) and 3.217 ± 1.860 cm/s (after the valve). Although, the velocity of the blood flow can be varies depends on the condition of the subject itself.

4. Conclusion

In conclusion, from the clinical experiments done, the purpose of the study is to diagnose the early-stage of Deep Vein Thrombosis (DVT). The parameters that had been measured were the wall displacement and blood flow velocity of the vessel. These parameters are important factors in evaluating the vessel condition. The elasticity of the vein was calculated based on the measurement proposed, that shown the difference of the vessel condition for different weight categories. In the future, the clinical data of DVT patient will be obtained, so that the comparison between of those parameters on the DVT patient and of the subjects with no histological DVT could be realized. The comparison will also be refered as the validation to predict the early-stage of DVT.

References

- [1] University of Rochester Medical Center, 'Deep Vein Thrombosis (DVT) /Thrombophlebitis'. Retrieved from <http://www.urmc.rochester.edu/encyclopedia> on 25th September 2013.
- [2] Society of Interventional Radiology, 2013, 'Deep Vein Thrombosis Overview'. Retrieved from http://www.ctcdvt.com/what_is_dvt.html on 28th September 2013.
- [3] American Academy of Orthopaedic Surgeons, 2009, 'Deep Vein Thrombosis'. Retrieved from <http://orthoinfo.aaos.org/topic.cfm?topic=a00219> on 25th September 2013.
- [4] James D. Fraser, MD, David R. Anderson, MD, 1999, 'Deep Venous Thrombosis: Recent Advances and Optimal Investigation with US', Departments of Radiology (J.D.F.) and Medicine (D.R.A.), Queen Elizabeth II Health Sciences Centre, 1278 Tower Rd, Halifax, Nova Scotia, Canada, Radiology, Apr 1999, Vol. 211:9–24.
- [5] E. Gregory Thompson, MD, Jeffrey S. Ginsberg, MD, 2010, 'D-dimer test for deep vein thrombosis'. Retrieved from <http://www.webmd.com/dvt/d-dimer-test-for-deep-vein-thrombosis> on 20th October 2013.
- [6] Stephanie Sippel, Krithika Muruganandan, Adam Levine and Sachita Shah, 2011, 'Review Article: Use Of Ultrasound In The Developing World', *International Journal Of Emergency Medicine* 2011, 4:72, doi:10.1186/1865-1380-4-72 .
- [7] Juan N. Useche, MD, Alfredo M. Fernández de Castro, MD, Germán E Galvis, MD, Rodolfo A. Mantilla, MD and Alvaro Ariza, MD, 2008, "Use of US in the Evaluation of Patients with Symptoms of Deep Venous Thrombosis of the Lower Extremities", Department of Radiology, Palermo Clinic, Bogotá, Colombia (J.N.U., R.A.M.); Department of Radiology, University Hospital of San Ignacio, Bogotá, Colombia (A.M.F.C., G.E.G.); and Department of Diagnostic Radiology, Clinica Nueva, Bogotá, Colombia (A.A.), *RG* Vol. 28, No. 6, 1785-1797.
- [8] Jack Hirsh and Agnes Y. Y. Lee, 2002, "How we diagnose and treat deep vein thrombosis", *BLOOD*, 1 May 2002 , Vol. 99, NO. 9, 3102-3110.
- [9] The Whiteley Clinic, 2001-2013, 'Blood Flow In Arteries'. Retrieved from http://deep-vein-thrombosis.co.uk/blood_flow_arteries.htm on 3rd December 2013.
- [10] Mamta Juneja , Parvinder Singh Sandhu, 2009, 'Performance Evaluation of Edge Detection Techniques for Images in Spatial Domain', *International Journal of Computer Theory and Engineering*, Vol. 1, No. 5,1793-8201.
- [11] J. Hirsh, J. Hoak, 1996, 'Management of deep vein thrombosis and pulmonary embolism. A statement for healthcare professionals. Council on Thrombosis (in consultation with the Council on Cardiovascular Radiology), American Heart Association.', *Circulation* (1996), Volume: 93, Issue: 12, Pages: 2212-2245.
- [12] Walter F. Boron, Emile L. Boulpaep, 2008, 'Elastic Properties Of Blood Vessels', *Medical Physiology*, Saunders, ISBN-10: 1416031154 ISBN-13: 978-1416031154.
- [13] Sara Dummmler, Stefan Eichhorn, Christian Tesche, Ulrich Schreiber, Bernhard Voss, Marcus-André Deutsch, Hans Hauner, Harald Lahm, Rüdiger Lange and Markus Krane, 2011, 'Pulsatile ex vivo perfusion of human saphenous vein grafts under controlled pressure conditions increases MMP-2 expression', 1German Heart Center Munich at the Technische Universität München, Department of Cardiovascular Surgery, Lazarettstrasse 36, D-80636 Munich, Germany.

- [14] Ernst O. Attinger, 1969, 'Wall Properties of Veins', *IEEE Transactions On Bio-Medical Engineering*, Vol. BME-16, NO. 4, 253-261.
- [15] Nabeel Kouka, MD, MBA, Len Nass, PhD, William Feist, PhD, 'Femoral Vein Blood Flow Velocities', Compression Therapy Concepts, S. Plainfield, NJ 07080.

